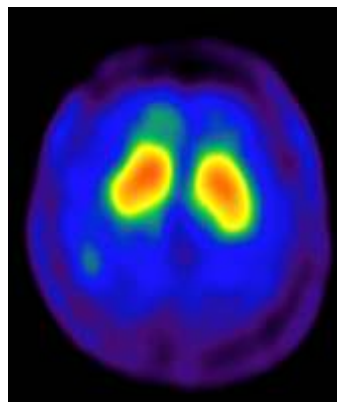


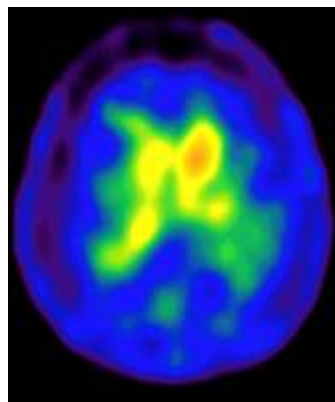
Nuclear Medicine

Parkinson Disease in ^{99m}Tc TRODAT Scan (Radioactive Technetium TRODAT Scan)

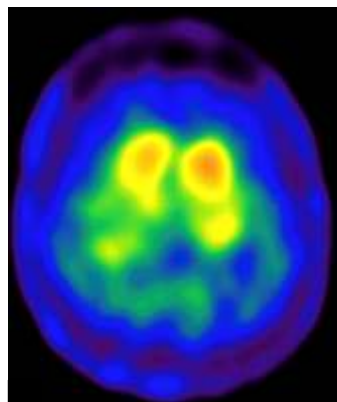
65 years old male developed slowness of movements, feels exhausted on minimal exertion, memory disturbances, mood swings and frequent falls His routine lab investigations and radiological investigations were unremarkable.



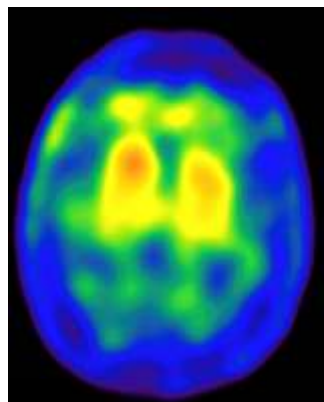
Essential Tremors with normal ^{99m}Tc TRODAT uptake



Parkinson Disease
(Left sided dominant symptoms)



Parkinson Disease: (Symmetrical
Symptoms: Putamen Degeneration)



Multisystem Degeneration

^{99m}Tc – TRODAT (tracer) Scan demonstrated asymmetrical basal ganglia tracer uptake indicating decreased tracer uptake in the Caudate Nucleus and Putamen because of degeneration and dysfunction. Helps to differentiate other causes of movement disorders

Dr. E. Prabhu