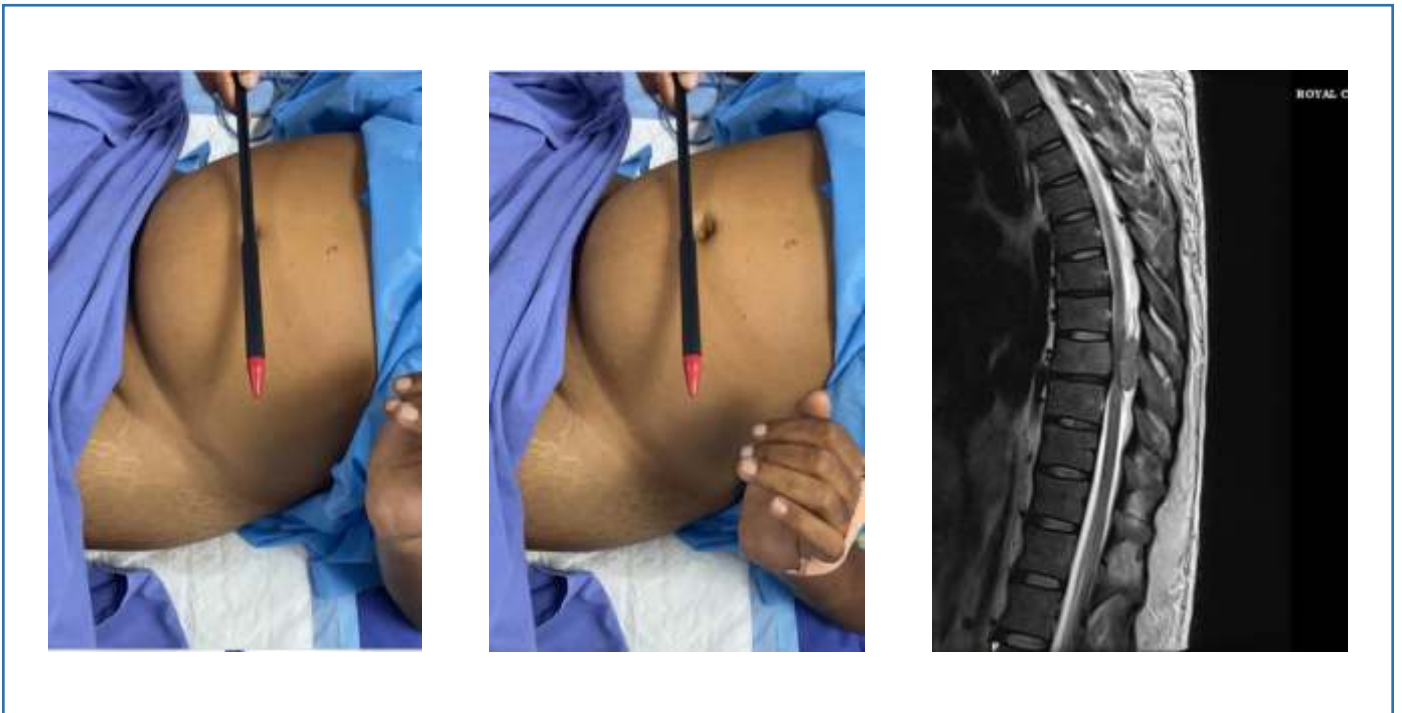


Clinical Sign

This patient presented with paraparesis that progressed over 3 days.
Beevor's sign was positive
MRI showed an extra medullary tumour compressing the cord at D8



Beevor's sign indicates differential weakness of the abdominal muscles with the stronger upper abdominal muscles pulling the umbilicus upward upon head and neck flexion from a supine position. It is a localising sign in spinal cord pathology and localises the lesion to T 10 spinal level and T 7 vertebral level. It is also noted in ALS and facioscapulohumeral muscular dystrophy

Dr. Vijayan
Neurologist, Royal Care Hospital, Coimbatore