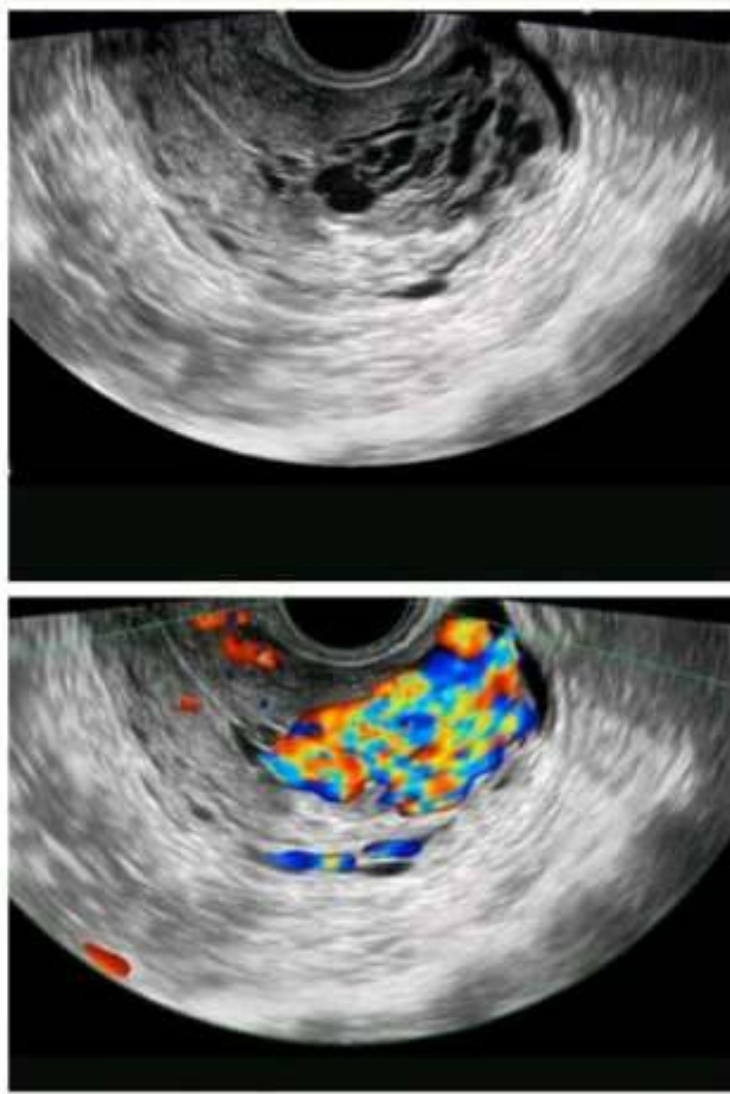


## OBG



Greyscale sonography shows areas of subtle myometrial inhomogeneity, tubular spaces within the myometrium...

When color doppler is switched on it

Typically shows serpiginous/tubular anechoic structures within the myometrium with low resistance (RI 0.2-0.5), high-velocity flow pattern...

### ***What's the Diagnosis?***

Uterine AV malformation