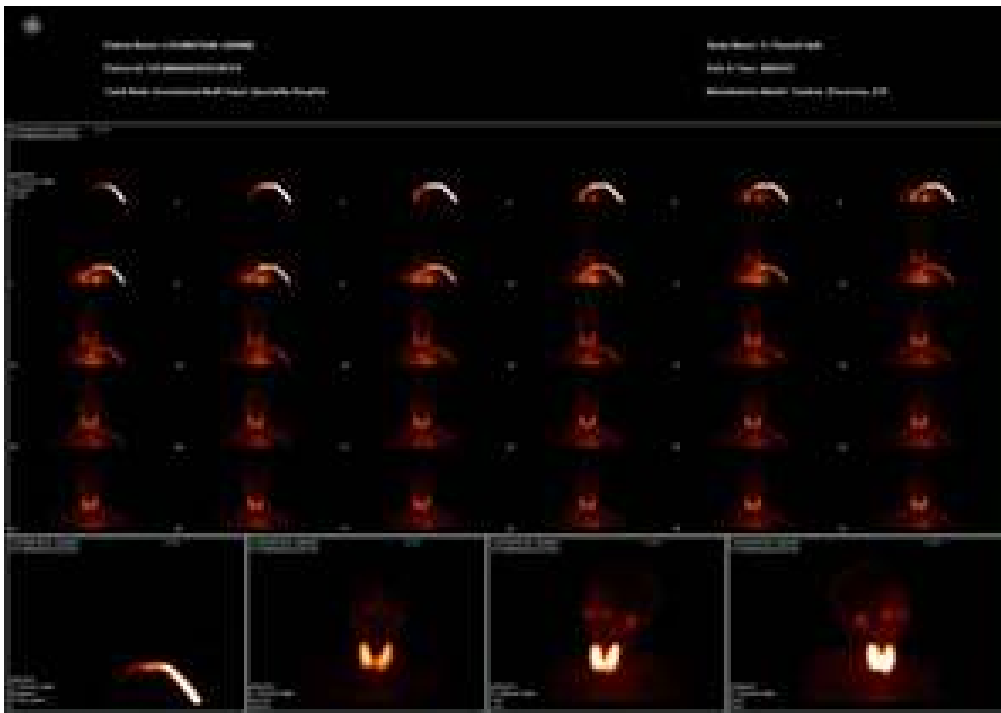


Nuclear Medicine

Toxic Multinodular Goiter in $^{99m}\text{TcO}_4$ (Radioactive Technetium Scan) 49 years old male with history of progressive weight loss and occasional tremors in his hands. His physicians noticed goiter. He was extensively investigated for an occult malignancy as his Serum Thyroid Function Tests were unremarkable.



$^{99m}\text{TcO}_4$ (Radioactive Technetium Pertechnetate Scan) demonstrated increased blood flow in both lobes of the Thyroid gland, during early images. Delayed Static images demonstrate that both lobes are enlarged and have increased and inhomogeneous tracer concentration indicating Toxic Multinodular Goiter. He was apparently treated with Carbimazole and he had been irregular on his medications.

Dr. E. Prabhu