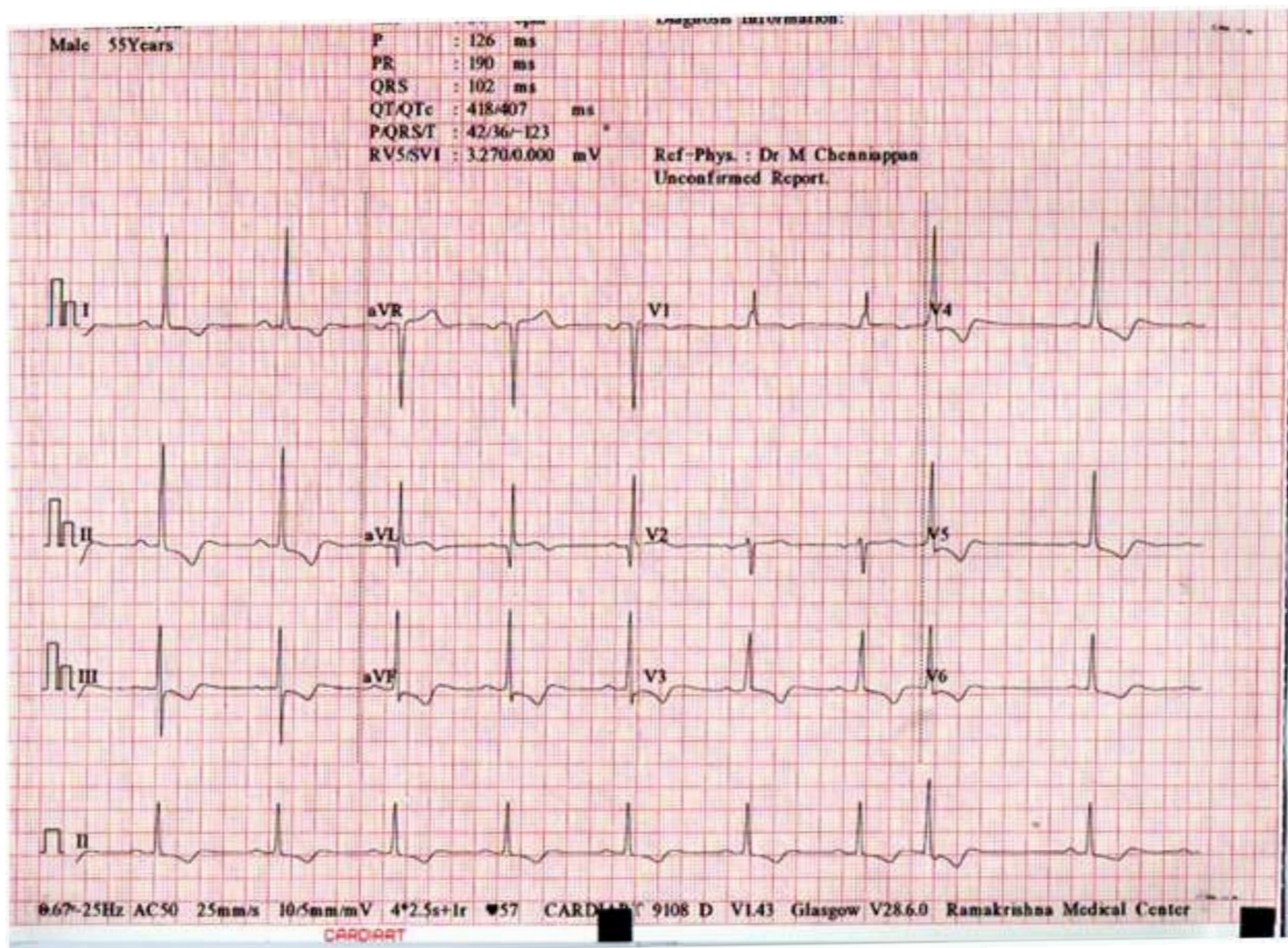


# ECG Excursions

Let us begin the journey of ECG EXCURSIONS with the following ECG

Ecg No.1 : Routine ECG of 55 year old male with known heart disease



What's the correct answer?

- a. Posterior wall MI
- b. Right Ventricular hypertrophy
- c. Hypertrophic cardiomyopathy
- d. RBBB
- e. None of the above

*Dr. M. Chenniappan, Trichy*