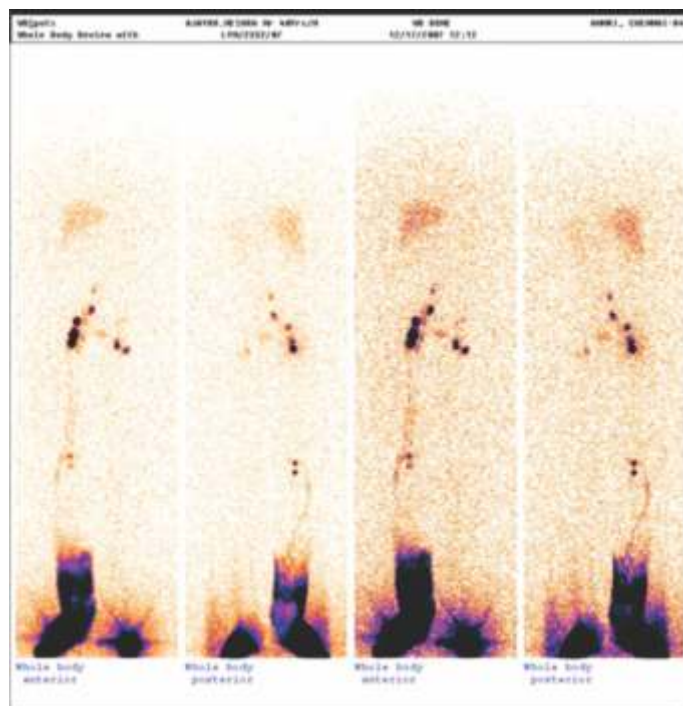


Nuclear Medicine

Refractory Bipedal Oedema Evaluation by Lymphoscintigram



40 years old male with bipedal oedema for more than 5 years duration. He has history of Road Traffic accident earlier. Lymphoscintigram was performed using ^{99m}Tc albumin nano-colloid injection in the 1st webspace of both lower limbs.

Dermal reflux is because of extravascular lymph transport through dermal lymphatics, after destruction of local lymphatics.

Lymphoscintigram helps to noninvasively assess pathways of lymphatic drainage, distinguish lymphatic oedema from lipidemia, myxedema and other causes of lower limb oedema, and identify sentinel nodes, quantification of lymphatic flow and high-risk patient identification for refractory lymphoedema development following axillary / inguinal node rection.

Dr. E. Prabhu.
*Head, Institute of Nuclear Imaging & Molecular Medicine,
Tamil Nadu Government Multi Super Speciality Hospital, Chennai*