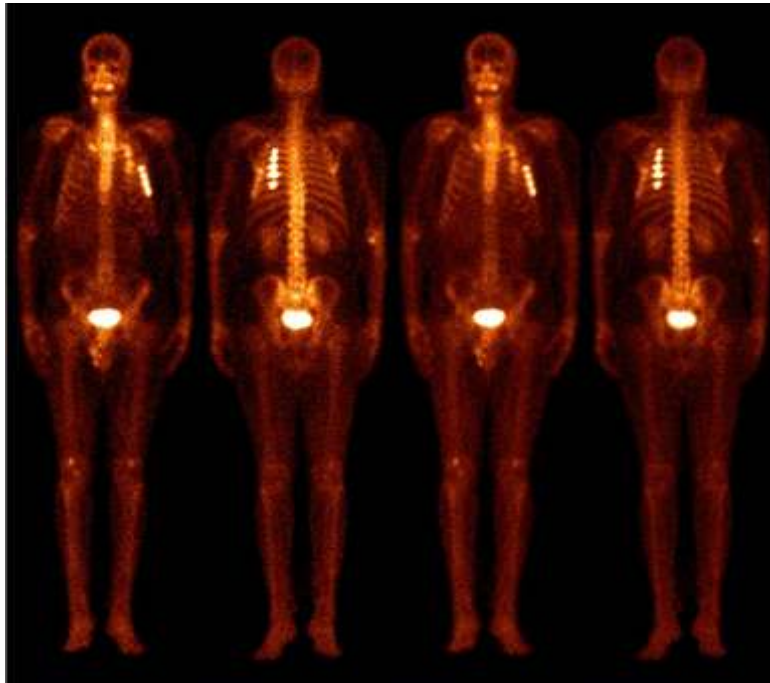


Nuclear Medicine

^{99m}Tc MDP Bone Scans in Chest Pain Evaluation

60 years old man with H (o) Chest Pain for 2 months duration. All his cardiac investigations and Chest X – Ray (PA view) were normal. We performed a ^{99m}Tc MDP Whole Body Bone Scan as the patient gave history of accidental fall while taking bath.



There is intense and asymmetrical tracer uptake in multiple ribs of the Left hemithorax, in a linear pattern, indicating rib fractures.

^{99m}Tc MDP was discovered in 1960 by McAfee and Gopal Subramanian. This tracer gets adsorbed to the bone crystals and there is almost symmetrical tracer distribution in Normal Individuals.

Dr. E. Prabhu.
Head, Institute of Nuclear Imaging & Molecular Medicine,
Tamil Nadu Government Multi Super Speciality Hospital, Chennai