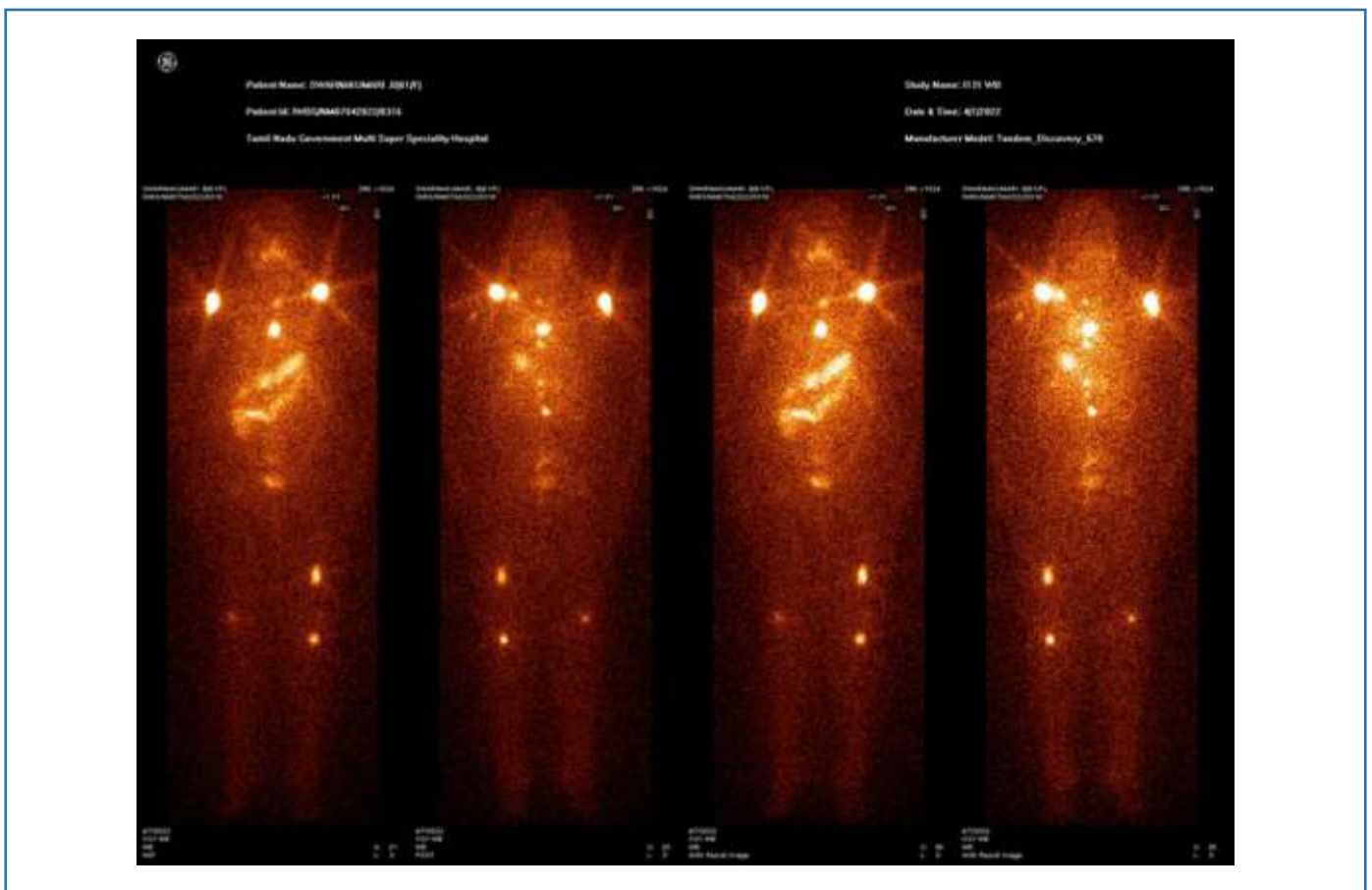


Nuclear Medicine

Thyroid Malignancy in ^{131}I (Radioactive Iodine Whole Body Scan)

61 years old female with generalized body pain for few months, not relieved with symptomatic treatment by her family physician. Her blood tests were unremarkable. She is not diabetic nor hypertensive. She was found to have curvilinear neck scar in her Thyroid region. She informed that she had undergone surgery for Thyroid swelling 12 years ago and has been taking 1 tablet Eltroxin, every morning since then.



^{131}I (Radioactive Iodine) Whole Body Scan demonstrates multifocal areas of intense and asymmetrical tracer concentration in her shoulders, sternum, multiple vertebrae, and both femurs—metastatic thyroid malignancy. She was treated with 100 mCi ^{131}I , suppressive Thyroxine Therapy and 6 monthly follow – up by estimation of Serum Thyroglobulin.

Dr. E. Prabhu