

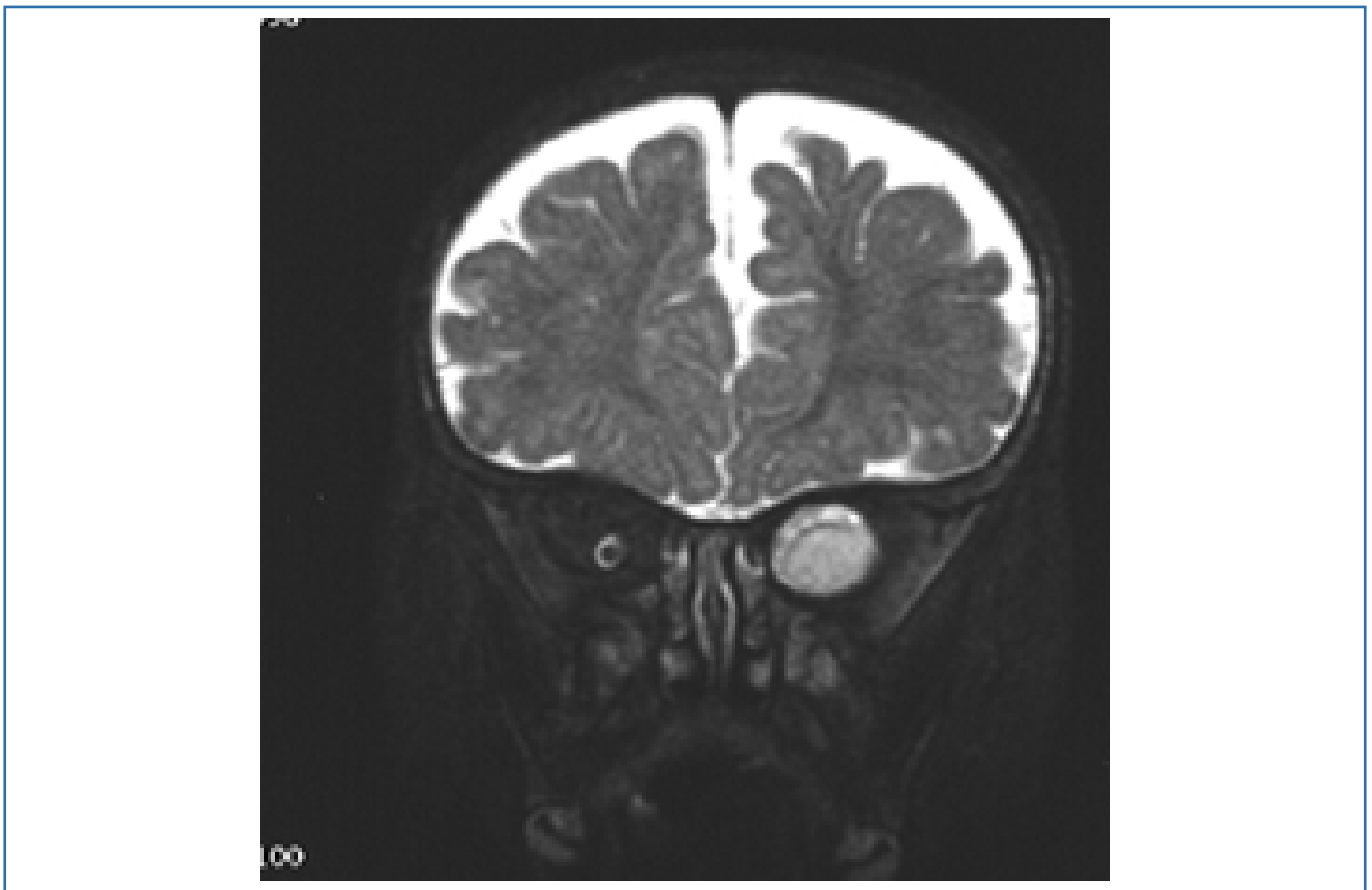
Image Corner

Question 2: 12 year old child with exophthalmos.

Which side is the exophthalmos?

What are the possible cause of retro orbital mass in child?

What other clinical features to look for?



Answer 2 : Optic nerve glioma at left orbit.

Other causes of retroorbital masses include – hemangioma, meningioma, rhabdomyoma.

These can be associated with neurofibromatosis type 1 and therefore related clinical findings – skin, brain and spinal features to be looked for (including bare orbit!)

Dr. Anbarasu