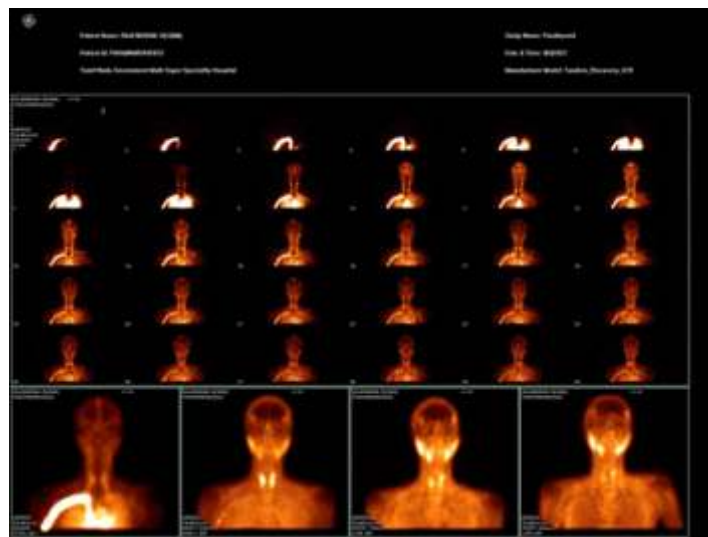


Nuclear Medicine

Parathyroid Adenomas in ^{99m}Tc MIBI Scan (Radioactive Technetium Sestamibi Scan) 19 years old male with history of recurrent cramps and body pain for about 3 months. His physical examination and routine blood tests were unremarkable. However, his Serum Calcium was higher than normal limits and Serum PTH is just above the normal limits.



mTc Sestamibi (tracer) Parathyroid Scan revealed diffusely increased tracer concentration in the Thyroid gland region. SPECT CT reconstruction demonstrates increased tracer uptake in the Parathyroid glands located at the upper pole of Right lobe region as well as lower pole of Left lobe indicating adenomas.

